

Rollin K. Daniel  
Péter Pálházi

# Rhinoplasty

An Anatomical  
and Clinical Atlas

 Springer

---

# Rhinoplasty

---

Rollin K. Daniel · Péter Pálházi

# Rhinoplasty

An Anatomical and Clinical Atlas

Rollin K. Daniel, MD  
Department of Plastic Surgery  
University of California Irvine  
Newport Beach  
California  
USA  
rkdanielmd2@gmail.com

Péter Pálházi, MD  
Department of Anatomy  
Histology & Embryology  
Semmelweis University  
Budapest  
Hungary  
peterpalhazi@gmail.com

ISBN 978-3-319-67313-4      ISBN 978-3-319-67314-1 (eBook)  
<https://doi.org/10.1007/978-3-319-67314-1>

Library of Congress Control Number: 2018935421

© Springer International Publishing AG 2018

This work is subject to copyright. All rights are reserved by the Publisher, whether the whole or part of the material is concerned, specifically the rights of translation, reprinting, reuse of illustrations, recitation, broadcasting, reproduction on microfilms or in any other physical way, and transmission or information storage and retrieval, electronic adaptation, computer software, or by similar or dissimilar methodology now known or hereafter developed.

The use of general descriptive names, registered names, trademarks, service marks, etc. in this publication does not imply, even in the absence of a specific statement, that such names are exempt from the relevant protective laws and regulations and therefore free for general use.

The publisher, the authors and the editors are safe to assume that the advice and information in this book are believed to be true and accurate at the date of publication. Neither the publisher nor the authors or the editors give a warranty, express or implied, with respect to the material contained herein or for any errors or omissions that may have been made. The publisher remains neutral with regard to jurisdictional claims in published maps and institutional affiliations.

Printed on acid-free paper

This Springer imprint is published by Springer Nature  
The registered company is Springer International Publishing AG  
The registered company address is: Gewerbestrasse 11, 6330 Cham, Switzerland

---

## Preface

A Rhinoplasty Revolution has begun, which will dramatically alter how we perform the operation. It is comparable in its impact to the changes that occurred following widespread adoption of the open approach. Rather than being based on visualization, the current revolution is driven by new anatomical insights. One example is the concept of the “bony cap,” which has repudiated the decades-old belief of a distinct bony hump that required en bloc removal. In contrast, we can easily rasp off the bony cap and then modify the underlying cartilage vault directly. The revolution extends to tip surgery, where we now analyze and surgically manipulate the soft tissue facets as well as the cephalic-caudal border relationship of the lateral crus.

Because limited exposure has often caused rhinoplasty surgery to be shrouded in mystery, an anatomical atlas is a necessity. We have decided to emphasize each anatomical area and the associated surgical techniques in both cadavers and clinical material, followed by clinical case studies. Chapter 1 emphasizes the five-layer composition of the soft tissue envelope using both serial cadaver dissections and sonogram studies. Three different dissection planes are illustrated, followed by detailed demonstration of nine nasal ligaments. Clinical cases illustrate how to manage cases with both thick skin and thin skin.

Chapter 2 details the “three-crus” concept of the alar cartilages and the direct linkage between surface aesthetics and the underlying anatomy. The medial crus, with its footplate and columellar segment, represents the pedestal of the tip complex. Appropriately, tip suturing is emphasized for the middle crus, with ten different sutures shown in depth. The concept of “intrinsic tip projection” as it relates to the middle crus is shown convincingly. The lateral crus, with its associated alar ring, is discussed as it relates to alar malposition and a range of turn-under or turn-over flaps. All of these findings are illustrated in a clinical case where a major tip change is achieved simply by repositioning and supporting the displaced alar cartilages.

Chapter 3 is an “exposed” look at the osseocartilaginous vault, which is minimally visualized in a routine rhinoplasty. Currently, surgeons see the tip cartilages far more than the dorsum, which may explain why dorsal deformities are now the tell-tale sign of a previous rhinoplasty. The new concept of a “bony cap” shifts the operation away from a destructive “bony hump reduction” to more of a modification of the underlying cartilaginous vault. Cadaver dissection allows one to see for the first time the true location of the various osteotomies. Implementation of piezoelectric instrumentation has lowered the location of the lateral osteotomies to the nasofacial groove and reintroduced complete osteotomies, albeit with maintenance of periosteal and mucosal support.

Chapter 4 deals with the septum and valves, while emphasizing both anatomical chokepoints and dynamic collapse at multiple points. A range of septal surgery is demonstrated clearly in cadavers, as it is rarely seen clinically owing to limited visualization. These techniques range from caudal relocation to repair of dorsal disjunction to subtotal and total septoplasties where rigid fixation is critical. Five different valvular checkpoints are illustrated, including both their pathology and their clinical treatment. Ultimately, the concept of an “integrated valvular collapse” is introduced, which begins at the internal valve angle and progresses to the lateral wall before collapsing the external valve.

Chapter 5 on the nasal base demonstrates clearly why cadaver dissections are so important for rhinoplasty surgeons. Simply put, the nasal base has never been seen before in this detail. New insight is provided into the columellar base, the soft tissue facets, the tela subcutanea cutis, and the alar rim. Instead of an obligatory filler chapter, one has the opportunity to understand all seven areas of the nasal base, from their anatomy to surgical procedures.

Chapter 6 details how to harvest the various graft materials (septum, concha, rib, dermis) and convert them to surgical grafts. Obviously, the number of grafts is unlimited, but all of the most common ones are illustrated. Caudal and septal extension grafts are discussed in detail, as is the role of fascia. The use of massive composite grafts from the concha will be new for many readers, along with the use of diced cartilage for peripyrimiform augmentation. The role of rib grafts is reviewed from composite reconstruction to structural reconstruction for the destroyed nose.

Chapter 7 is offered as a foundation operation for the beginning surgeon. It is not presented as the definitive answer or the perfect procedure, but rather as a starting point for those learning the operation. Based on training a large number of residents and fellows and receiving their follow-up comments once in practice, the senior author (RKD) knows that this foundation will lead to a “good” result in the average nose. The more complex the problem, the more often one must modify the basic technique, but the surgeon must start somewhere, and this operation will minimize complications. The validity of this operation is confirmed by the junior author (PP), whose first surgical procedure as an intern was not excision of a lipoma, but rather a rhinoplasty.

A few words on how this book was assembled. It is truly an atlas, with emphasis on visual learning. The anatomical photographs are extraordinary and every step has been taken to maximize their clarity. The text was written to fit the illustrations rather than the other way around. We do not cite every reference in an academic fashion, but rather have elected to go with longer “reading lists” and to reference authors in the text by last name and date of publication. The format is similar to that of *Mastering Rhinoplasty*.

In closing, there are numerous people we need to thank for their assistance over the past 3 years. The junior author would like to express his gratitude to his mentor Dr. Lajos Patonay. All of the dissections were done in his laboratory at the Anatomy Institute, Semmelweis University, Budapest. He provided an opportunity to join the team as a medical student and gave access to the laboratory and research facilities. Without his support, it would not have been possible to create this atlas. Sincere thanks also go to Dr. Gyongyver Molnar, Dr. Tamas Karasz, Istvan Kristof, and Lajos Herczeg.

The senior author wishes to thank his office staff, especially Judy An, who cajoled the patients to return for their follow-up exams and photographs. All of the clinical cases were done at Newport Beach Surgery Center, whose entire staff, from Front Desk to Postoperative Care, are true professionals dedicated to the highest in patient care. In the Operating Room, thanks go to the “Four Graces” (Breanna Green, Jhaave Reyes, Windy Bess, and Petra Wirsching), who made sure the blue towels were correct and no blood was visible in the endless series of photographs.

Ultimately, this atlas is our gift to the rhinoplasty community, with the hope that surgeons will see more clearly the linkage between nasal anatomy and rhinoplasty, for the benefit of their patients.

Newport Beach, CA, USA  
Budapest, Hungary

Rollin K. Daniel, MD  
Péter Pálházi, MD

---

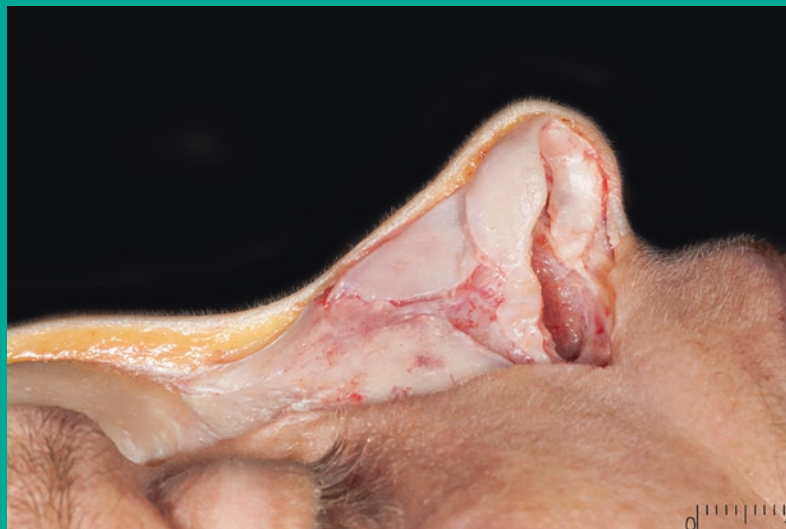## Contents

<b>1</b>	<b>Surface Aesthetics and Soft Tissue Envelope</b> .....	<b>1</b>
<b>2</b>	<b>Alar Cartilages</b> .....	<b>49</b>
<b>3</b>	<b>Osseocartilaginous Vault</b> .....	<b>113</b>
<b>4</b>	<b>Septum, Turbinates, Valves</b> .....	<b>165</b>
<b>5</b>	<b>Nasal Base</b> .....	<b>213</b>
<b>6</b>	<b>Grafts</b> .....	<b>259</b>
<b>7</b>	<b>A Standard Rhinoplasty Operation</b> .....	<b>307</b>
	<b>Index</b> .....	<b>339</b>



# 1

# Surface Aesthetics and Soft Tissue Envelope

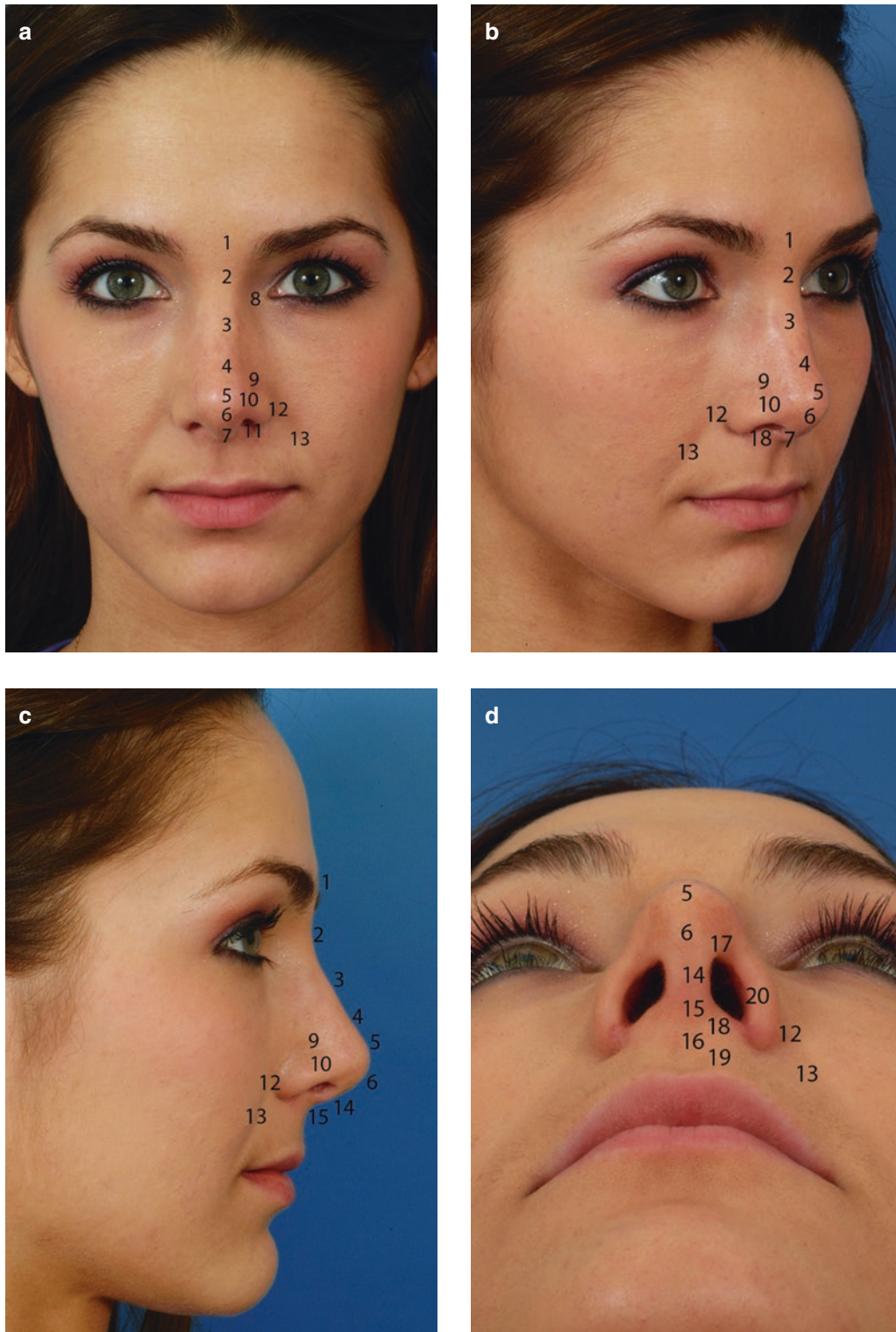


Why is the soft tissue envelope (STE) so important in the planning and execution of a rhinoplasty operation? Put simply, the nasal skin envelope covers the underlying osseocartilaginous structures, preventing the surgeon from seeing the true nasal deformity preoperatively and often limiting or compromising the postoperative result. Most surgeons consider skin redraping and remodeling to be the greatest uncertainty in the healing process. The essential purpose of this chapter is to teach the reader how to “see through” the skin and understand the underlying tip and dorsal anatomy.

Intraoperatively, three different dissection planes are demonstrated for treating patients with thin, normal, or thick skin. In most cases, a dissection in the avascular deep areolar plane below the superficial musculoaponeurotic system (SMAS) is preferred. In a thick-skin STE, the initial dissection is done in the superficial areolar sub-dermal plane followed by a sub-SMAS dissection with removal of the intervening soft tissue. In thin-skin cases, the dissection plane is in the subperichondrial and subperiosteal plane. Postoperatively, sequential sonograms allow the surgeon to evaluate the healing process and guide the decision to utilize triamcinolone acetonide (Kenalog®) for excessive scar tissue or isotretinoin (Accutane®) for dermal thickening. Ultimately, we are now able to make major changes in nasal shape without being limited by a noncompliant skin sleeve.



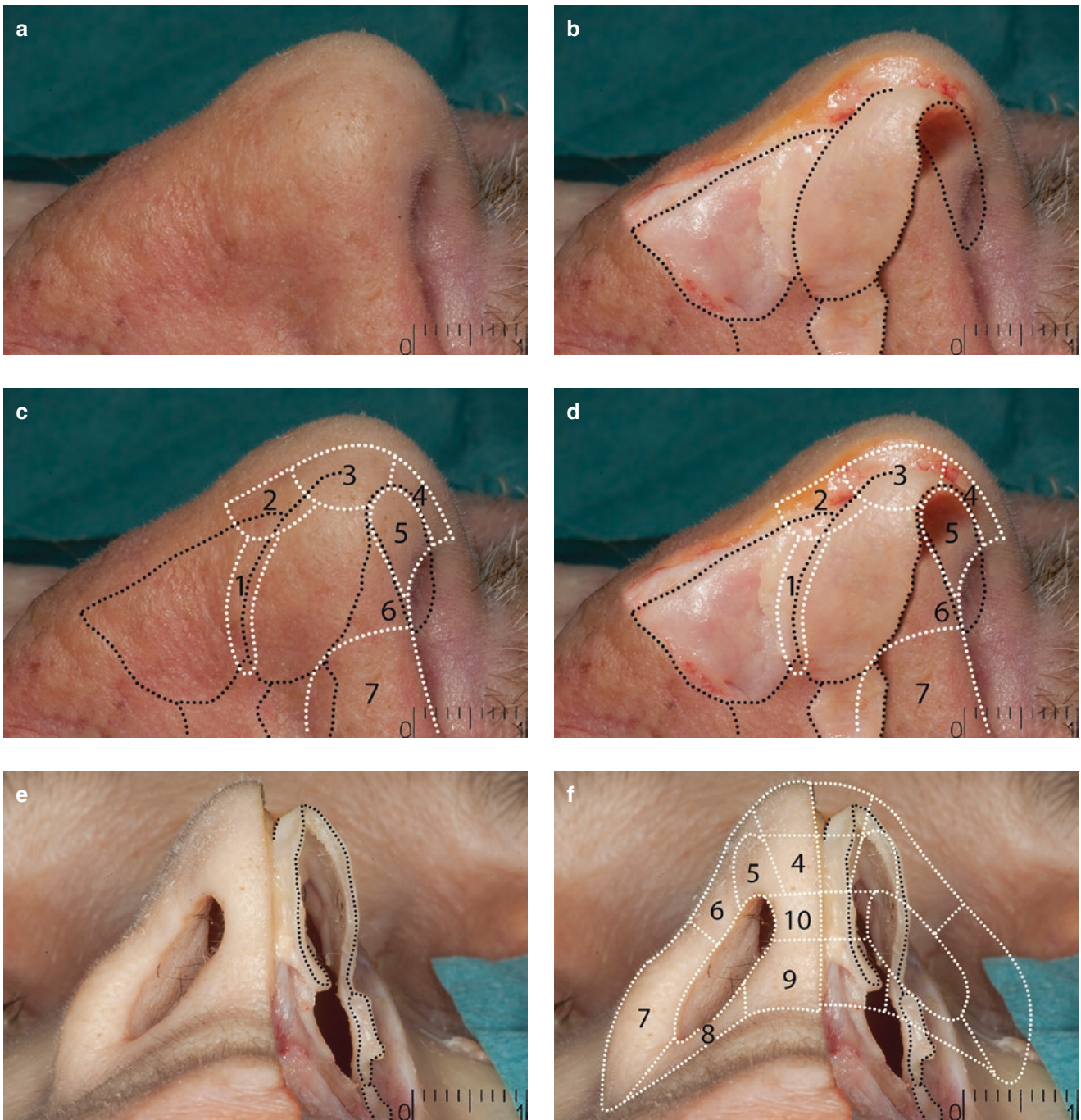
## SURFACE LANDMARKS



**Fig. 1.1 (a–d)** Surface landmarks

Figure 1.1 illustrates the surface landmarks of the nose: (1) glabella, (2) nasion, (3) rhinion (keystone point), (4) supratip, (5) tip, (6) infratip lobule, (7) columella, (8) medial canthal ligament, (9) supraalar groove, (10) alar groove, (11) nostril, (12) alar crease, (13) nasolabial fold, (14) columellar pillar, (15) columellar base, (16) philtrum, (17) soft tissue facet (triangle), (18) nostril sill, (19) philtral crease, (20) alar sidewall.

## TOPOGRAPHIC LANDMARKS

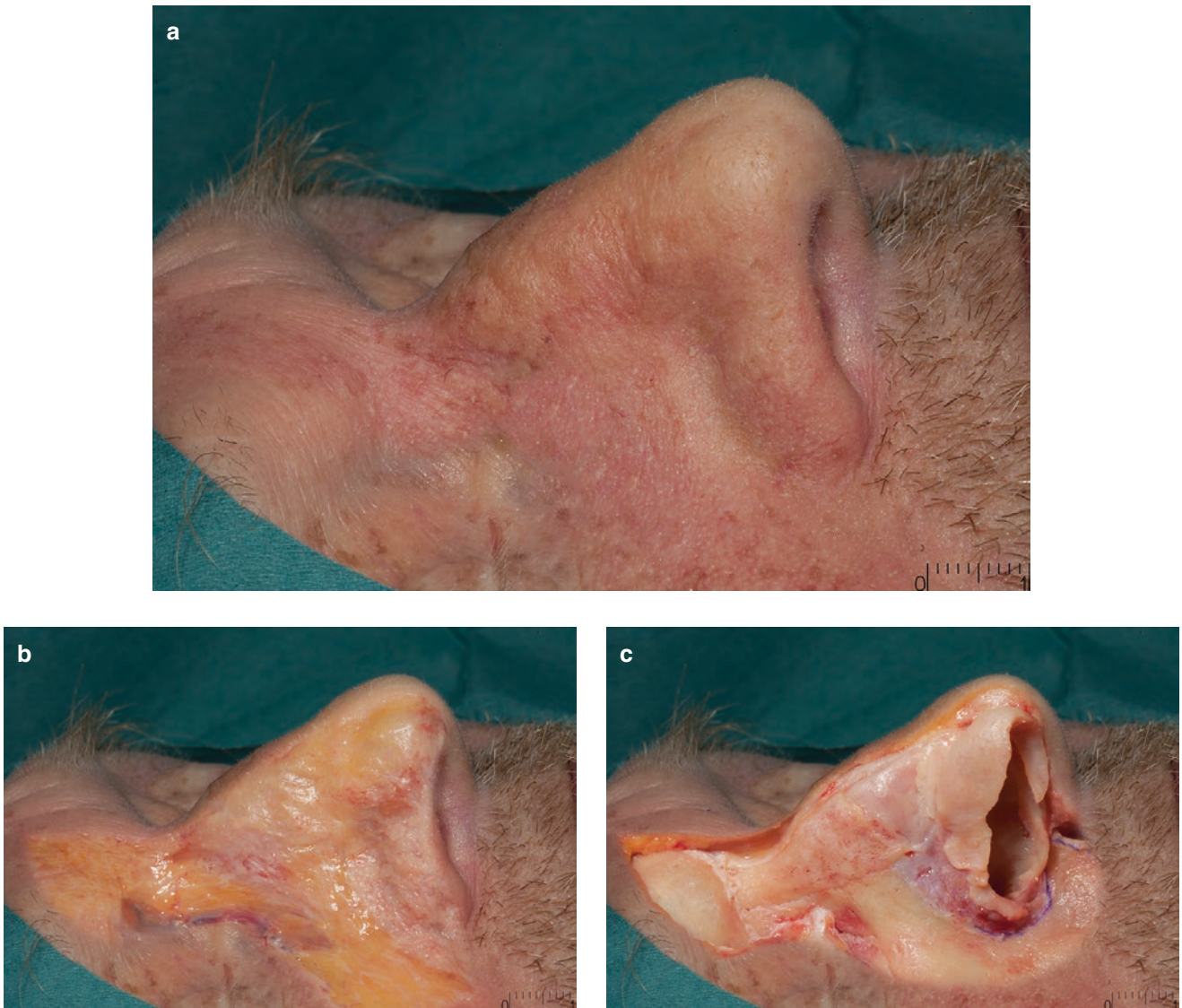

**Fig. 1.2 (a–f)** Topographic landmarks. Note: all photographs are taken with a fixed position camera allowing exact overlays.

Figure 1.2 demonstrates topographic landmarks and areas: (1) scroll area, (2) supratip, (3) tip, (4) infralobular triangle, (5) soft tissue facet, (6) nostril rim, (7) alar lobule, (8) nostril sill, (9) columellar base, (10) columellar pillar.



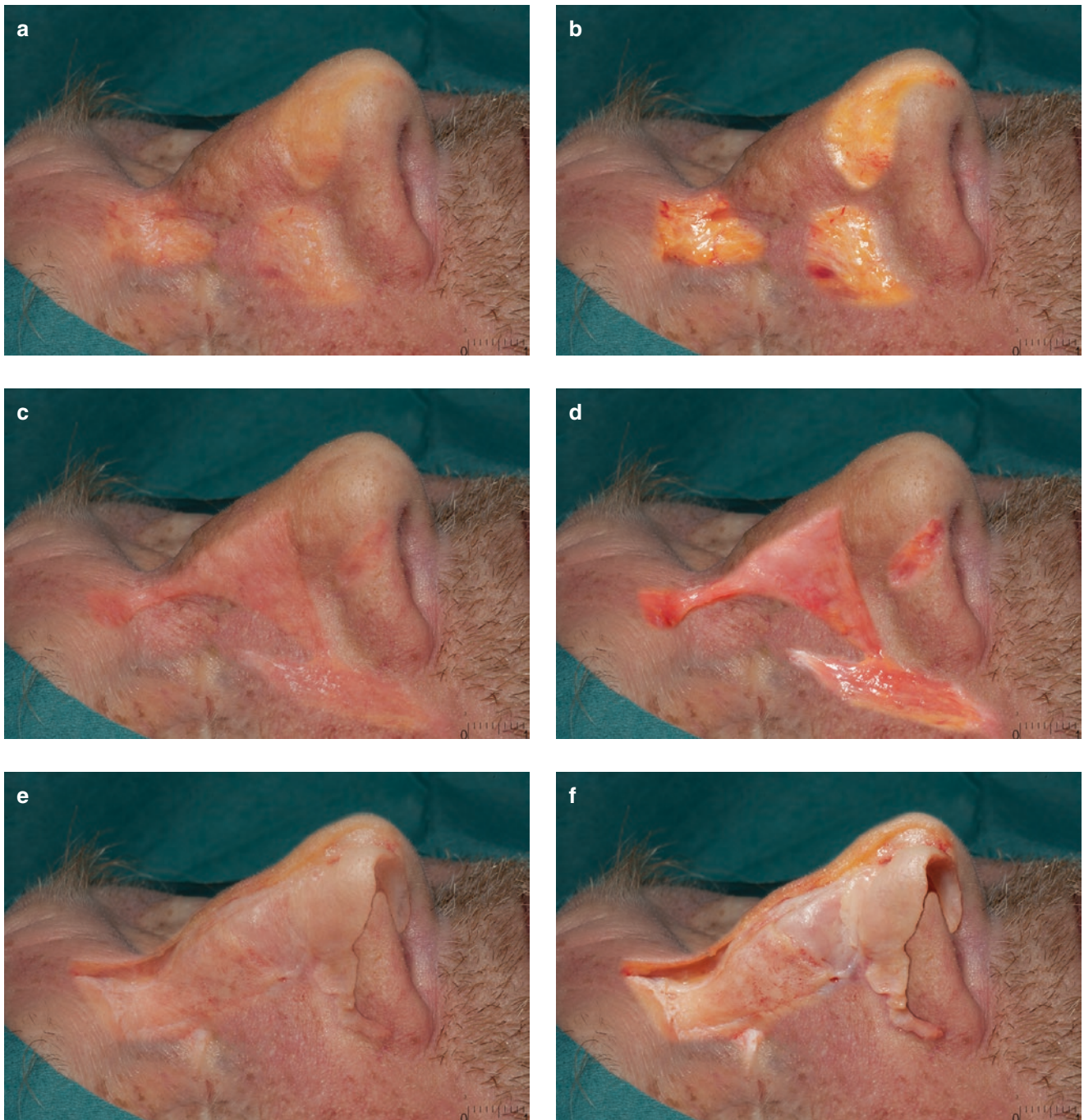
## ANATOMICAL LAYERS



**Fig. 1.3** The soft tissue envelope of the nose: (a) Skin. (b) Subcutaneous fat and superficial musculoaponeurotic system (SMAS). (c) Osseocartilaginous skeleton underlying the soft tissue envelope. Note: all photographs are taken with a fixed position camera which records accurate sequential dissection.

Surgeons must develop the ability to “see through” the mask of the skin envelope and visualize the underlying osseocartilaginous foundation of the nose. Figure 1.3 was created with a “fixed position” camera, which allowed an exact sequential delayering of the nose. The STE is composed of the epidermis, dermis, subcutaneous fat, and the superficial musculoaponeurotic system (SMAS), which varies dramatically in component thickness from cephalic to caudal in the same individual, and even more dramatically between patients. The skin itself can be divided into a thin upper half and a thicker lower, sebaceous half. In many ethnic noses, the surgeon is challenged to visually *integrate* the two parts of the skin envelope, often with solid dorsal cartilage grafts. The subcutaneous fat is localized in the supratip area, the radix, and the lateral nasal wall. If one thinks of *layers* as opposed to *planes*, there are five layers: (1) skin, (2) superficial areolar layer, (3) SMAS, (4) deep areolar layer, and (5) perichondrium-periosteum.

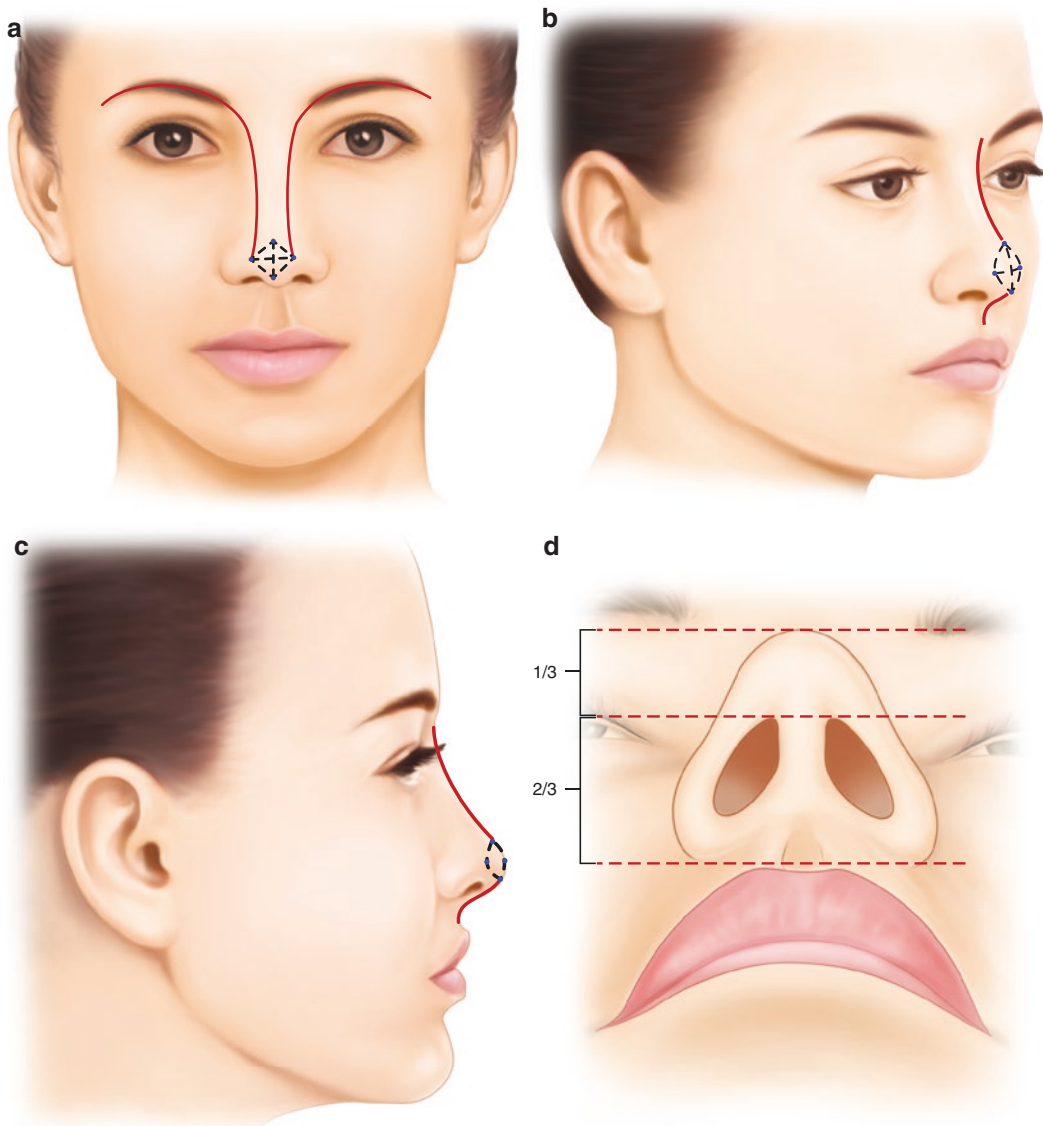
## ANATOMICAL LAYERS



**Fig. 1.4** (a, b) Subcutaneous fat pads. (c, d) Muscles. (e, f) Osseocartilaginous skeleton of the nose

The two areolar layers become relatively avascular *dissection planes*. The nasal SMAS integrates and transmits the contraction forces of the nasal musculature (Fig. 1.4). Preservation of the SMAS is desirable from a functional perspective and in maintaining adequate long-term padding of the skin. Recently, surgeons have begun to dissect in a subperichondrial-subperiosteal plane that maintains the integrity of the STE and reduces damage to the neurovascular structures (Çakir et al. 2012).

## SURFACE AESTHETICS

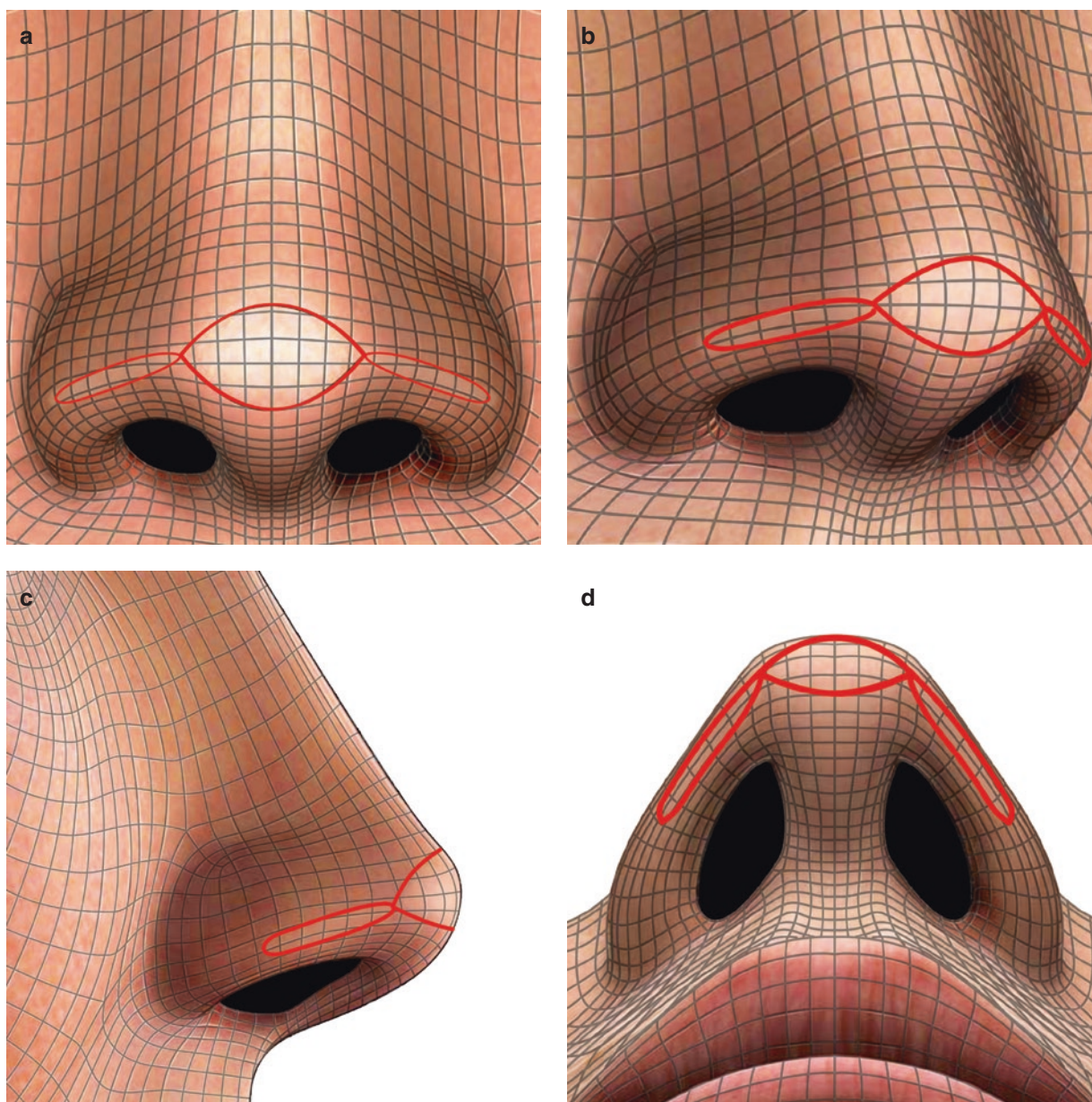


**Fig. 1.5** (a–d) Surface aesthetics according to Sheen (1978)

Until publication of *Aesthetic Rhinoplasty* in 1978 by Jack Sheen (Sheen 1978), surgeons analyzed the nose in almost an architectural manner using angles, lines, planes, and profilometers (Fig. 1.5). Sheen's emphasis on aesthetics revolutionized preoperative analysis and postoperative evaluation, especially as regards tip surgery. On front view, he emphasized the divergent concave dorsal lines that connect the superciliary ridge of the orbit through the radix to the tip. He visualized the tip as two equilateral geodesic triangles with a common base, the length being the intercrural distance. The apex of the superior triangle is the point of tip differentiation, and the apex of the inferior triangle is the point of columellar lobular junction. Interestingly, the apogee of the intercrural line should be the highest point of the tip.



## SURFACE AESTHETICS

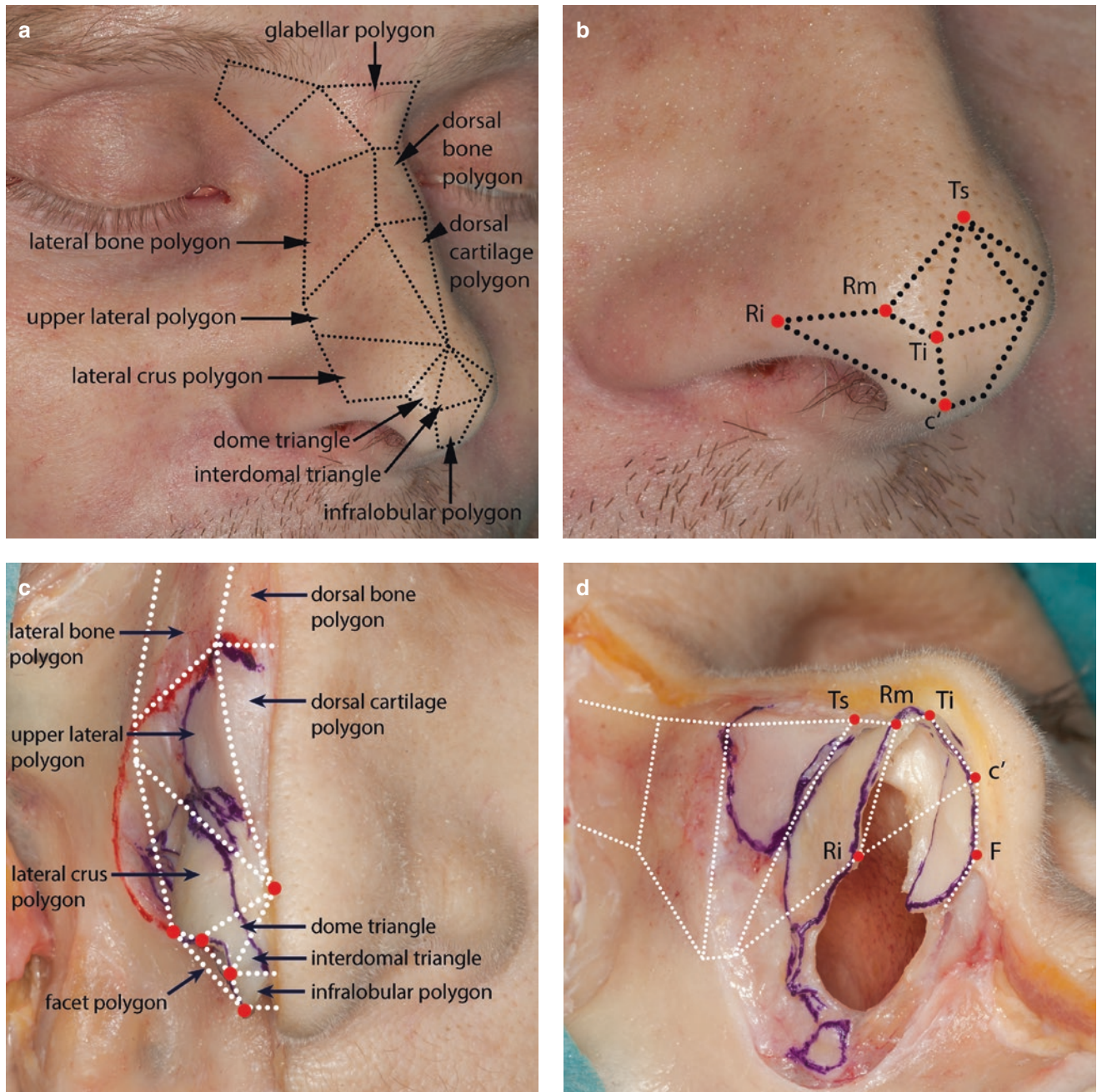


**Fig. 1.6** (a–d) Surface aesthetics according to Toriumi (2006)

Toriumi (2006) introduced the concept of *nasal tip contour* as a series of surface *highlights and shadows* created by underlying anatomical high points and low points (Fig. 1.6). Specifically, the tip is represented by a horizontal tip *highlight* corresponding to the domes, with continuation of the highlight as an elevated ridge in continuity with the alar lobule. Surgically, this tip highlight can be created with a domal onlay graft, while the elevated ridge along the alar margin will be accentuated by an alar rim graft. Equally important, a *shadow* in the supratip region continues laterally into the alar groove, thus setting off the tip. Excision of cephalic crura emphasizes the supratip breakpoint and moves it caudally, setting off the tip. The linkage between surface aesthetics and surgical techniques is readily apparent in Toriumi's operative procedures.



## POLYGONS



**Fig. 1.7** Cakir's concept of the aesthetic nasal polygons. (a, b) Surface polygons. (c, d) Points defining the polygons of the nasal tip

Çakir et al. (2012) and Çakir (2016) introduced the concept of *polygons* for analyzing the aesthetics of the nose, based on artistic principles from drawing and sculpture. Essentially, the nasal polygons are geometric forms derived from a composite of lines, shadows, and highlights, with specific proportions and breakpoints (Fig. 1.7). The osseocartilaginous vault is comprised of two bony polygons (dorsal and lateral) and two cartilaginous polygons (dorsal and lateral). Importantly, Çakir notes that the dorsal aesthetic lines are not straight, but rather “fusiform”—narrow in the radix, wider at the keystone, and narrow again at the supratip. On basilar view, one sees the infralobular, columellar, and footplate polygons.